

Peritoneal Carcinomatosis with Displaced IUCD

Pankaj Deka^{1,*}, Amal Chandra Kataki¹, Debabrata Barmon¹, Bibhuti Bhushan Borthakur² and Sushruta Shrivastava¹

¹Dept. of Gynaecological Oncology; ²Dept. of Surgical Oncology, Dr. B. Borooah Cancer Institute, Guwahati, Assam, India

Abstract: Intrauterine contraceptive device (IUCD) has been widely used as a safe, economic, effective and reversible method of contraception. IUCDs are generally well accepted with good compliance but complications sometime occur. Uterine perforation is a rare complication with an incidence of one in 1000 procedures. Whether a displaced IUCD in the peritoneum can lead to carcinogenesis is a matter of debate. We report a case of peritoneal carcinomatosis with displaced Lippes loop.

A 70 year female with ascites who was diagnosed as peritoneal carcinomatosis and administered two cycle of chemotherapy presented to this institution for further management. She was evaluated, administered four more cycles of chemotherapy and taken for exploratory laparotomy. At laparotomy a Lippes loop was found adherent to the colon and omentum. Total abdominal hysterectomy, bilateral salpingo-oophorectomy, total omentectomy and transverse colon resection with end to end anastomosis was done. Post operative histopathology showed adenocarcinoma in colon and omentum located around the loop. Uterus, ovaries and rest of the bowel were free of disease. She received two more cycles of chemotherapy after operation. She has completed follow up of 6 weeks after completion of treatment with clinically no evidence of disease.

Keywords: Intrauterine contraceptive device (IUCD), Lippes loop, Peritoneal carcinomatosis, Adenocarcinoma, Chemotherapy.

INTRODUCTION

Intrauterine contraceptive device (IUCD) has been widely used as a safe, economic, effective and reversible method of contraception. The first generation IUCDs - Lippes loop was introduced in 1965 and was in use till 1980 [1]. It had higher expulsion rate (6.7%) as compared to Copper containing IUCDs (3.5%) [2], hence it was subsequently replaced by copper containing devices and recently hormone releasing IUCDs have been also introduced. IUCDs are generally well accepted with good compliance but complications sometime occur. Uterine perforation is a rare complication with an incidence of one in 1000 procedures [3]. Displacement of IUCDs to an extra uterine site in the peritoneal cavity is an uncommon complication which may remain without specific symptom and therefore evade detection for a long period [4]. Displaced IUCDs are not incriminated as a cause of cancer but is a possibility. We are reporting a case of peritoneal carcinomatosis in a woman with displaced lippes loop remaining intraperitoneal for 35 years.

Case History

Mrs. BD a 70 yrs female, P₈L₈, 20 years postmenopausal and hypertensive, who developed

ascites and was diagnosed as peritoneal carcinomatosis and administered two cycle of chemotherapy (paclitaxel 200mg and carboplatin 200mg), presented to this institution for further management on 02/17/2012. She was found to have pallor and bilateral pedal edema and ascites but no palpable mass. Her height was 140 cm and weight was 48 kg. Investigation showed Hemoglobin (7.3gm%), serum CA125-317.68 IU/L, CEA 2.3 IU/L AFP 1.11 IU/L, Creatinine-0.7mg%. CT scan showed massive ascites with thickened peritoneum and omentum and a radio-opaque foreign body in peritoneum. Ascitic fluid cytology showed adenocarcinoma.

There was a history of Lippes loop insertion 35 years back. After insertion of loop she conceived and delivered twice. There was no history of removal of the loop. There was no history of cancer in her family.

The dose of paclitaxel and carboplatin which she received outside was considered suboptimal for an estimated BSA of 1.34 m² and AUC 5. She was therefore administered four cycles more of paclitaxel 200 mg and carboplatin 400 mg. CT scan after four cycles showed complete radiological response and a radio-opaque foreign body in peritoneum (Figure 1). She underwent exploratory laparotomy on 6/5/2012. On exploration there was a matted mass of transverse colon with omentum and its mesentery, undersurface of diaphragm, liver surface, paracolic gutters, peritoneum, uterus, bilateral tubes and ovaries were found normal.

*Address corresponding to this author at the Dr. B. Borooah Cancer Institute, Gopinath Nagar, Guwahati- 781016, Assam, India; Tel: +919864046803; Fax: 0361-2472636; E-mail: drpankajdeka@gmail.com

Total abdominal hysterectomy, bilateral salpingo-oophorectomy, total omentectomy and transverse colon resection with end to end anastomosis was done. Section of the operated specimen showed a displaced IUCD (Lippe's loop) embedded in the matted mass (Figure 2).

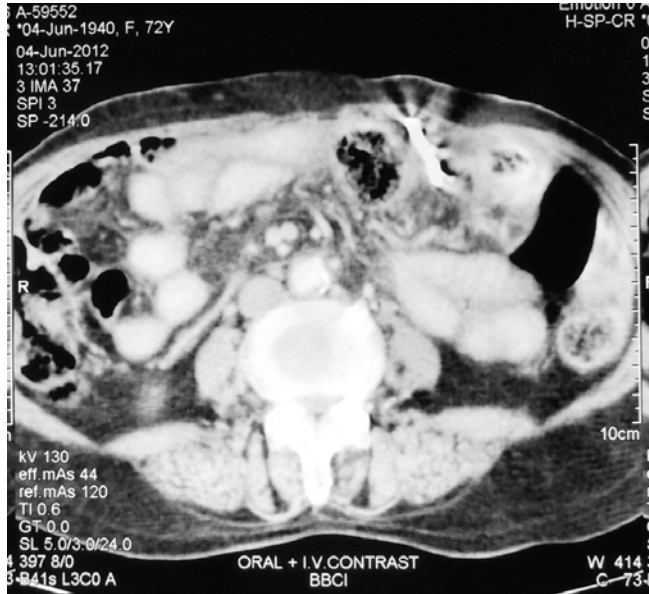


Figure 1: CT Scan showing the radio-opaque foreign body in the peritoneum.

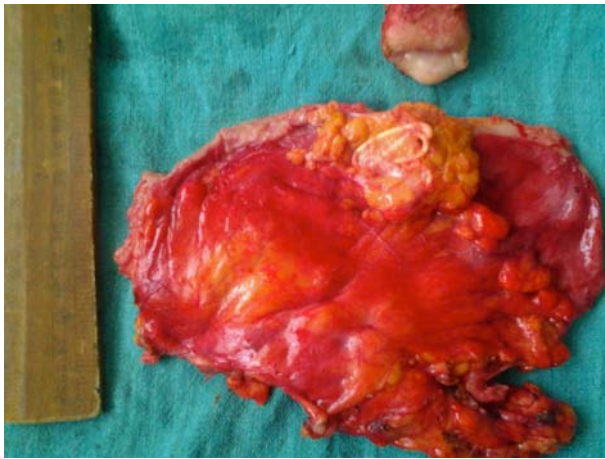


Figure 2: Operative specimen showing a displaced IUCD (Lippe's loop) embedded in the matted mass of colon and omentum.

Post operative histopathology showed foci of adenocarcinoma on the serosal surface of the colon adherent to the foreign body only. Omentum was infiltrated by sheets of adenocarcinoma cells. Uterus and bilateral ovaries were unremarkable (Figure 3). She received two more cycles of chemotherapy with paclitaxel 200 mg and carboplatin 400 mg. At present the patient has completed 5 months of follow-up and clinically there is no evidence of disease.

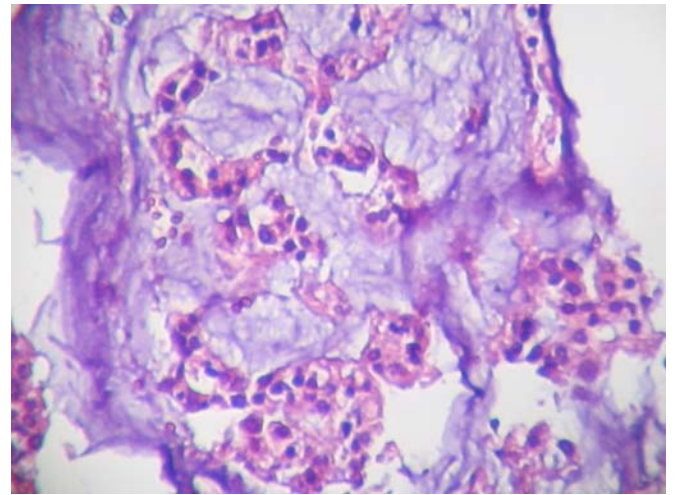


Figure 3: Histopathology slide of specimen showing adenocarcinoma.

DISCUSSION

Uterine perforation may occur during IUCD insertion and its incidence is about 1 in 1000 procedures [5]. Risk factors for perforation include insufficient experience in IUCD placement, immobile uterus, retroverted uterus and presence of myometrial defect. Only 15% of displaced IUCD lead to complications in adjacent viscera [6]. A displaced IUCD generally migrates to proximity of recto sigmoid junction and urinary bladder [3, 7]. However migration may also occur to omentum, peritoneum, peri-appendicular area, small intestine, ovary, gall bladder and sub diaphragmatic area. Uterine perforation may occur during insertion or later. Most of the perforation is by copper containing devices [8] and they generally produce symptoms from inflammatory reaction to copper [9]. Non-copper containing inert IUCDs such as Lippes loop causes little symptoms, hence are detected only incidentally [9]. In our case, the mode of perforation is difficult to ascertain but it is assumed that the IUCD was lying intraperitoneally for a long period. Though, it is difficult to ascertain whether the displaced Lippes loop is the source of adenocarcinoma, in the present case the residual foci of adenocarcinoma were found only around lippes loop. Bharati *et al.* [9] reported a case of adenocarcinoma of caecum in a 75 yrs old woman with Lippes loop which migrated through tubal fimbria which was inserted 40 years back.

A patient with IUCD should be alerted about the possibility of its migration. A follow-up after 3-6 weeks of insertion or after next menstrual period to ensure that IUD is in place and information about kind of IUCD and when to have her IUCD removed or replaced

should be given to the patient. Regular self examination for missing threads is useful in the early detection of migration of the IUCD and she should visit her doctor immediately in such situation. This is the second case report of a probable association between abdominal adenocarcinoma and a displaced IUCD. More and more similar cases should be reported as and when found.

REFERENCES

- [1] Zakin D, Stern WZ, Rosenblatt R. Complete and partial uterine perforation and embedding following insertion of intrauterine devices. *Obstet Gynaecol Surg* 1981; 36: 335-53.
<http://dx.doi.org/10.1097/00006254-198107000-00001>
- [2] Farr G, Amatya R, Acosta M, Ekwempu C, Kisininci H. Clinical performance of the TCu 380A and Lippes Loop IUDs in three developing countries. *Contraception* 1995; 52: 17-22.
[http://dx.doi.org/10.1016/0010-7824\(95\)00119-U](http://dx.doi.org/10.1016/0010-7824(95)00119-U)
- [3] Kandýrali E, Topcuoglu MA, Semercioz A, Metin A. Double intrauterine device: presented with protruding urethral stone. *Marmara Med J* 2008; 21: 61-63.
- [4] Hao-Ming C, Teng-Wei C, Chung-Bao H, *et al.* Intrauterine contraceptive device appendicitis: A case report. *ISSN 1007-9327 CN 14-1219/R world J Gastroerol* 2005; 11(34): 5414-15.
- [5] Mechanism of action, safety and efficacy of intrauterine devices. Report of a WHO scientific group. *World health Organ Tech Rep Sec* 1987; 753: 1.
- [6] Verma U, Verma N. Ovarian embedding of a transmigrated intrauterine device: a case report and literature review. *Arch Gyne Obs* 2009; 280: 275-78.
<http://dx.doi.org/10.1007/s00404-008-0882-2>
- [7] Darlongn LM, Panda S, Topna N, Hajong R. Colonoscopic retrieval of migrated Copper-T. *J Min Ac Surg* 2009; 5: 40-42.
- [8] Zieren J, Moebius B, Zieren B, Menenakos C. Combined laparoscopic colonoscopic approach for the removal of a migrated intrauterine contraceptive device penetrating the sigmoid colon. *Gyne Surg* 2006; 3: 223-25.
<http://dx.doi.org/10.1007/s10397-006-0200-6>
- [9] Bharathi RS, Chakladar A, Kumari P. Mystery of the missing loop MJAFI 2011; 67: 177-78.

Received on 17-09-2012

Accepted on 15-10-2012

Published on 31-12-2012

DOI: <http://dx.doi.org/10.6000/1929-2279.2012.01.02.8>